TomoTherapy®
ACCURAY®

Hi·Art® Treatment System Case Study

CTrue™ adaptive lung

Original Treatment Plan

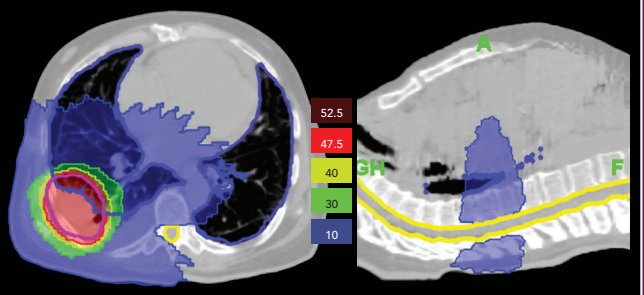

- 50 Gy in 25 fractions is prescribed to a mass in the right posterior lung
- Excellent cord sparing (maximum of approx. 8 Gy) is achieved via optimization of a helical IMRT delivery

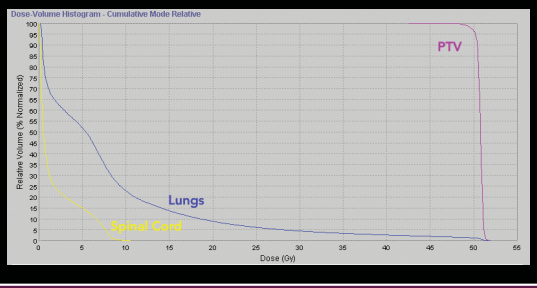

Hypothetical Delivery

Original plan image

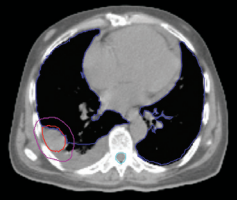

5 days into treatment
(~1cGy MVCT)

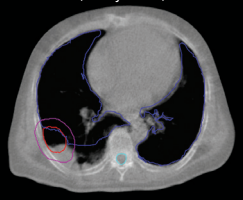

Registered image
(Green = Daily CT Grey = Planning CT)

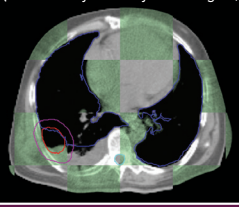

- Over a one week period, a progressive posterior shift of the tumor occurs due to edema drainage
- Daily patient alignment via external marks or bony anatomy would lead to a severe under-dosage of the tumor due to geographic miss

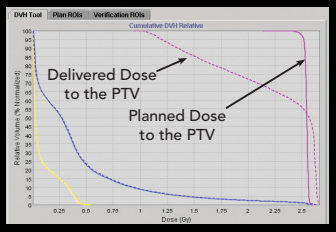

Dose calculation showing the results if treated by aligning to bone

Only ***DAILY*** 3D imaging reveals anatomical changes and their dosimetric impact at every fraction

Actual Delivery Using *CTrue* Technology

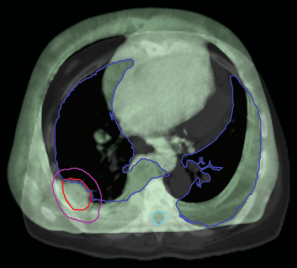

Registered images using PTV contour & dose to position tumor for treatment

- Using *CTrue* technology, the shifting tumor can be correctly aligned before every fraction and dose can be overlaid to check target coverage and organ sparing
- Spinal cord dose remains within tolerance thanks to TomoTherapy's helical delivery and treatment is continued with the initial plan up to and including the 5th fraction
- Taking advantage of *CTrue* images and adaptive therapy technology, the clinician decided that after the 5th treatment session the plan will be re-optimized for the remaining fractions

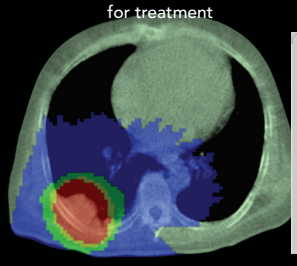

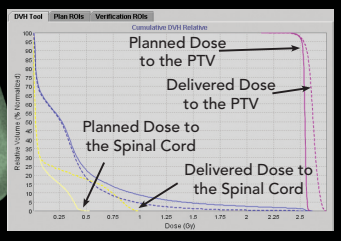

Dose calculated on the daily CT image

Adapted Plan

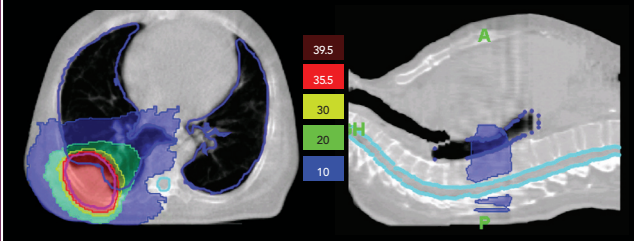

- Using *CTrue* technology, every daily image is suitable for treatment planning since pixel values are true representations of tissue density
- The day-5 *CTrue* image is used to re-plan the case using the true anatomy
- After re-optimization, the cord is once again spared effectively along with excellent dose coverage of the target at its new location
- *CTrue* provides true dose guidance

DVH for re-optimized plan, showing low cord dose and homogeneous target dose

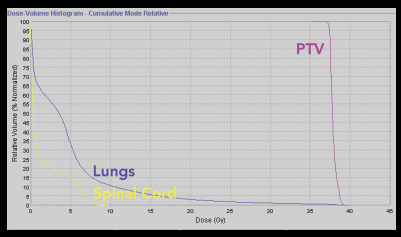

St. Agnes Hospital
Baltimore, MD | Dr. Richard Hudes, MD

M-CLN-020-1006